



PATIENT

Jake Palumbo

PRESENTING CLINICAL SIGNS

History: Grade II/VI systolic murmur; no coughing; no exercise intolerance. BP: 140-150mmHg.

SPECIES

Canine

ECHOCARDIOGRAM FINDINGS

2D, m-mode, color flow and Doppler imaging is available.

BREED

Spaniel Mix

Left ventricle: The LV diameter is normal with adequate myocardial function. LV wall thicknesses are normal.

Left atrium: The left atrium is mildly dilated.

Mitral valve: The mitral valve is mildly thickened with minima prolapse into the left atrial lumen. Mild eccentric mitral regurgitation with a normal velocity.

SEX

Male Neutered

Aortic valve/aorta: The aortic valve is normal in morphology and mobility. Normal aortic outflow velocity; laminar flow. No aortic insufficiency.

Right ventricle: Normal right ventricular diameter and morphology indicating no overt evidence of pulmonary arterial hypertension.

Right atrium: Normal RA dimension.

AGE

7 years

Tricuspid valve: The tricuspid valve appears normal with mild tricuspid regurgitation; normal velocity.

Pulmonic valve/pulmonary artery: The pulmonic valve is normal in morphology and mobility. No pulmonic insufficiency. Normal RVOT velocity; laminar flow.

Pericardium/other: No pericardial or pleural effusion noted. No obvious cardiac masses.

WEIGHT

25.2lbs

Heart rhythm: ECG reveals a sinus rhythm with an average HR of 110bpm.

2-Dimensional Measurements

Doppler Measurements

INTERPRETED BY

Maggie Machen
Lamy, DVM
DACVIM (Cardiology)

Ao diam (cm)	1.7
LA diam (cm)	2.2
LA:Ao (Swe)	1.3
IVS thickness (cm)	0.8
LVID diastole (cm)	3.3
PW thickness (cm)	0.8
LVID systole (cm)	1.7
FS (%)	47

PV Vmax (m/s)	0.8
AoV Vmax (m/s)	1.4
MR Vmax (m/s)	5.5
TR Vmax (m/s)	2.6
TR PG (mmHg)	28

IMAGING PERFORMED BY

Pamela Harrigan,
RDCS

INTERPRETATION OF THE FINDINGS

The cause of the murmur is chronic degenerative valve disease causing mild mitral and mild tricuspid regurgitation. Lack of significant left atrial enlargement indicates the current risk for complication is low. No concurrent issues such as systolic dysfunction or pulmonary hypertension are noted in this study. Assessment of progression in the future will help predict long term prognosis, which is highly variable at this stage (B1).

HOSPITAL NAME

Wood River Animal
Hospital

REFERRING VET

Dr. Rogoff

RECOMMENDATIONS

- In an asymptomatic dog without significant left atrial enlargement, no cardiac medications are clearly indicated.
- Omega fatty acid supplementation and mild salt restriction may be of some long-term benefit.
- Anesthetic risk is considered mild if needed. Cardiac protective drug choices (opioid/benzodiazepine premedication, propofol or alfaxalone induction, isoflurane gas) are recommended. Pre-oxygenate for 5-10 minutes prior to induction. Monitor for arrhythmias, hypotension, and hypoxia both intra and post-operatively and

INVOICE

20999

DATE

9/13/21



PATIENT

Jake Palumbo

intervene as necessary. Mild IV fluid restriction is recommended to avoid fluid overload. Avoid heart rate stimulating drugs such as atropine unless clinically indicated.

SPECIES

Canine

- Monitor for development of a cough, labored breathing, exercise intolerance or collapse episodes.

PLAN

BREED

Spaniel Mix

- Recommend conservative monitoring with a recheck echocardiogram in 6 months, sooner if any development of clinical signs.

SEX

Male Neutered

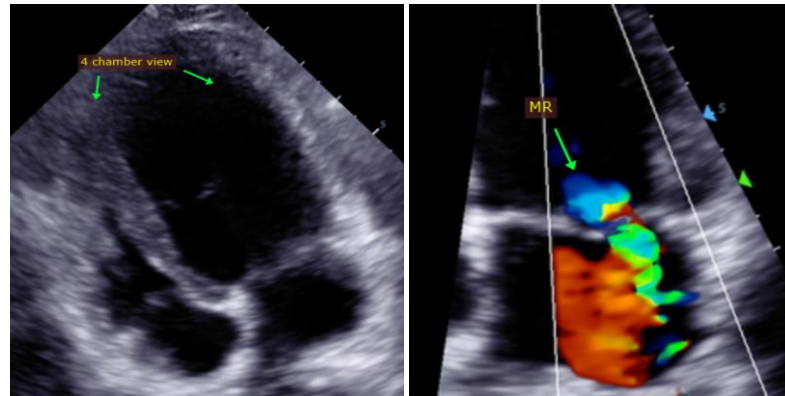
AGE

7 years

WEIGHT

25.2lbs

IMAGES



INTERPRETED BY

Maggie Machen
 Lamy, DVM
 DACVIM (Cardiology)

The information and recommendations provided are based on the images presented by the referring veterinarian. No evaluation can be communicated regarding pathology that was not visible in the image/video clips provided.

IMAGING PERFORMED BY

Pamela Harrigan,
 RDCS

Maggie Machen Lamy, DVM
 Diplomate of the American College of Veterinary Internal Medicine (Cardiology)
 info@sonopath.com

Thank you for this referral. This report was generated using transcription software, and minor dictation errors may be present. If the clinical or image interpretation does not parallel your findings or if I can be of any further assistance, please contact me.

HOSPITAL NAME

Wood River Animal
 Hospital

REFERRING VET

Dr. Rogoff

INVOICE

20999

DATE

9/13/21